



## Original Article

## Experience of double balloon enteroscopy

Ming-Yao Su<sup>a,b,c,\*</sup>, Wei-Pin Lin<sup>a,c</sup>, Cheng-Tang Chiu<sup>a,b,c</sup><sup>a</sup> Department of Gastroenterology and Hepatology, Linkou Chang Gung Memorial Hospital, Taoyuan, Taiwan, ROC<sup>b</sup> Chang Gung University College of Medicine, Taoyuan, Taiwan, ROC<sup>c</sup> Taiwan Association for the Study of Small Intestinal Diseases (TASSID), Taoyuan, Taiwan, ROC

Received March 3, 2017; accepted June 20, 2017

## Abstract

**Background:** To evaluate the experiences of double balloon enteroscopy (DBE) for obscure gastrointestinal bleeding.**Methods:** From October 2003 to November 2009, a total of 124 patients with obscure gastrointestinal bleeding were investigated using DBE. A total of 142 procedures (84 per oral and 58 per rectal route) were performed by the same endoscopist.**Results:** The average insertion time was 71.4 (20–199) minutes per-orally; the average insertion time was 139.2 min for the first 5 procedures, 109.4 min for 6–10 procedures, 76.6 min for 11–15, 66.4 min for 16–20, 67.4 min for 21–25, 59 min for 26–30, 66 min for 31–35, 52 min for 36–40, 42.9 min for 41–45, 44.6 min for 46–50, 42.2 min for 51–55, 38.6 min for 56–60, 44.6 min for 61–65, 37.8 min for 66–70, 38.8 min for 71–75, 44.3 min for 76–80, and 36.6 min for 81–84 procedures; there was no statistical difference after the first ten procedures.

The average insertion time was 92.1 (22–260) minutes per-rectally; the average insertion time was 159.6 min for the first 5 procedures, 98.4 min for 6–10 procedures, 86.6 min for 11–15, 76.4 min for 16–20, 82.4 min for 21–25, 75.0 min for 26–30, 78.2 min for 31–35, 72.4 min for 36–40, 68.2 min for 41–45, 66.9 min for 46–50, and 71.4 min for 51–58 procedures; there was no statistical difference after the first five procedures.

For the different genders there was no statistically significant difference. There were no differences regarding the diagnostic yield between the previous factors. The overall diagnostic yield was 82.4%.

**Conclusion:** DBE is a safe and effective means of diagnosing and managing patients with obscure gastrointestinal bleeding. However, because of its time-consuming, DBE has a learning curve to overcome before a physician can become an expert to achieve adequate insertion times with good diagnostic and therapeutic rates.Copyright © 2017, the Chinese Medical Association. Published by Elsevier Taiwan LLC. This is an open access article under the CC BY-NC-ND license (<http://creativecommons.org/licenses/by-nc-nd/4.0/>).**Keywords:** Double balloon enteroscopy; Gastrointestinal bleeding; Obscure

## 1. Introduction

Approximately 1–5% of patients with gastrointestinal bleeding could be classified as having obscure bleeding, defined as bleeding of an unknown origin that persists or recurs after a negative initial or primary colonoscopy and/or

upper endoscopy result.<sup>1–3</sup> The primary source of blood loss in patients with obscure gastrointestinal bleeding is the small bowel, although bleeding lesions located within the reach of standard upper endoscope or colonoscope may be overlooked during initial investigation.<sup>1</sup> Because of the free intraperitoneal location, the vigorous contractility, convolutions and the length of the small bowel, bleeding from this area is difficult to approach using a conventional endoscopy.<sup>3</sup> Push enteroscopy could detect only a limited portion of the proximal small bowel. Sonde-type enteroscopy is not popular, suffering the disadvantages of prolonged length of examination time, limited mucosal visualization and aggravated patient discomfort.<sup>1,3,4</sup> Moreover, other diagnostic modalities such as small

Conflicts of interest: The authors declare that they have no conflicts of interest related to the subject matter or materials discussed in this article.

\* Corresponding author. Dr. Ming-Yao Su, Department of Gastroenterology and Hepatology, Linkou Chang Gung Memorial Hospital, 5, Fushin Street, Gweishan district, Taoyuan 333, Taiwan, ROC.

E-mail address: [doctorsu@adm.cgmh.org.tw](mailto:doctorsu@adm.cgmh.org.tw) (M.-Y. Su).

<https://doi.org/10.1016/j.jcma.2017.06.020>

1726-4901/Copyright © 2017, the Chinese Medical Association. Published by Elsevier Taiwan LLC. This is an open access article under the CC BY-NC-ND license (<http://creativecommons.org/licenses/by-nc-nd/4.0/>).

Please cite this article in press as: Su M-Y, et al., Experience of double balloon enteroscopy, Journal of the Chinese Medical Association (2017), <https://doi.org/10.1016/j.jcma.2017.06.020>

bowel contrast studies, angiography and radionuclide bleeding scans are unsatisfactory due to their low yield or poor localization of lesion site.<sup>1</sup> Consequently, identifying and treating the source of obscure gastrointestinal bleeding is a clinical challenge.

Recently the clinical application of capsule endoscopy has marked a significant advance in diagnosing the cause of obscure gastrointestinal bleeding.<sup>5–8</sup> Capsule endoscopy is a noninvasive technique with high success rate for complete examination of the whole small bowel.<sup>6</sup> Compared with push enteroscopy and small bowel radiography, capsule endoscopy has been demonstrated to be superior in detecting the source of bleeding.<sup>9–12</sup>

Double-balloon enteroscopy (DBE), a new insertion method developed by Yamamoto et al., enables observation of the entire small bowel with high image quality and excellent maneuverability and enables to-and-fro examination, biopsy, and therapeutic intervention at any given site.<sup>13–15</sup> Therefore, double-balloon enteroscopy offers a good method for investigating the cause of obscure gastrointestinal bleeding. However, DBE is time consuming and a learning curve is needed. This study presented the personal experience and evaluated the factors that influence the learning curve of DBE for obscure gastrointestinal bleeding.

## 2. Methods

### 2.1. Patients

From October 2003 to November 2009, a total of 126 patients with obscure gastrointestinal bleeding were investigated using DBE in a tertiary medical center by retrospective analysis. The clinical form of bleeding was subdivided into obscure-overt ( $n = 114$ ), defined as recurrent passage of visible blood and obscure-occult ( $n = 12$ ), defined as recurrent iron deficiency anemia and/or recurrent positive fecal occult blood test. The group of patients consisted of 72 men and 54 women, with a mean age of 53.4 years old (range, 12–82 years old). The mean lowest hemoglobin level was 7.9 g/dl (range 3.2 g/dl to 11.8 g/dl). 24 patients (17 males and 7 females) had received abdominal surgery previously. To finish, the median duration of obscure bleeding prior to double-balloon enteroscopy was 8.4 months (range, 1–144 months). A total of 142 procedures (84 per oral route and 58 per rectal route) were performed. There were 16 patients received bi-direction routes of DBE and 12 patients were performed as total enteroscopy. All the procedures were performed by the same endoscopist who had performed more than 10,000 cases of colonoscopy previously. The insertion length was estimated by the sum of inserted length for every insertion sessions. Stopped the insertion when the enteroscope could not insert more but not only found the lesions. The target lesions were defined as compatible with previous findings of other studies, tumor-like lesions, active bleeders, or active inflammatory lesions.

### 2.2. The double-balloon enteroscopy system

The double-balloon enteroscopy system (Fujinon Inc., Japan) is a high resolution video endoscope with a flexible overtube. The therapeutic enteroscope was used (EN-450T5; Fujinon), which has an external diameter of 9.4 mm and a forceps channel of 2.8 mm. This endoscope has a working length of 200 cm, and a detachable balloon at its tip, and is used with a soft overtube 140 cm long with an additional balloon at the distal end.

The insertion route was determined based on the estimated location of the bleeding site according to the previous studies' guidance or clinical symptoms. There were 48 cases (38%) had suspected lesions (mostly tumor-like lesions) detected by other studies before enteroscopy. If no definite lesion was identified from the initial direction or if total enteroscopy was attempted, the deepest insertion site was tattooed with India ink and subsequent enteroscopy was performed from the opposite direction a few days later.

No specific preparation is required for the oral approach besides fasting for 6–8 h before the procedure. Enteroscopy from the rectal approach requires bowel cleansing as in colonoscopy. The premedication with demerol and midazolam were intravenously injected for minor conscious sedation. No general anesthesia was needed.

## 3. Results

Only the first four cases were performed using enteroscopy under fluoroscopic guidance for initial practice of DBE. The average insertion time was 71.4 (20–199) minutes per-orally and the diagnostic yield is 83.33%; while the average insertion time was 139.2 min for the first 5 procedures (diagnostic yield was 80%, mean inserted length  $360 \pm 40$  cm), 109.4 min for 6–10 procedures (diagnostic yield was 80%, mean inserted length  $410 \pm 60$  cm), 76.6 min for 11–15 (diagnostic yield was 80%, mean inserted length  $340 \pm 60$  cm), 66.4 min for 16–20 (diagnostic yield was 100%, mean inserted length  $360 \pm 60$  cm), 67.4 min for 21–25 (diagnostic yield was 80%, mean inserted length  $320 \pm 80$  cm), 59 min for 26–30 (diagnostic yield was 80%, mean inserted length  $340 \pm 80$  cm), 66 min for 31–35 (diagnostic yield was 80%, mean inserted length  $350 \pm 60$  cm), 52 min for 36–40 (diagnostic yield was 80%, mean inserted length  $380 \pm 40$  cm), 42.9 min for 41–45 procedures (diagnostic yield was 80%, mean inserted length  $310 \pm 80$  cm), 44.6 min for 46–50 procedures (diagnostic yield was 100%, mean inserted length  $340 \pm 60$  cm), 42.2 min for 51–55 procedures (diagnostic yield was 80%, mean inserted length  $300 \pm 80$  cm), 38.6 min for 56–60 procedures (diagnostic yield was 80%, mean inserted length  $360 \pm 60$  cm), 44.6 min for 61–65 procedures (diagnostic yield was 100%, mean inserted length  $320 \pm 80$  cm), 37.8 min for 66–70 procedures (diagnostic yield was 80%, mean inserted length  $360 \pm 60$  cm), 38.8 min for 71–75 procedures (diagnostic

yield was 80%, mean inserted length  $360 \pm 40$  cm), 44.3 min for 76–80 procedures (diagnostic yield was 80%, mean inserted length  $360 \pm 80$  cm), and 36.6 min for 81–84 procedures (diagnostic yield was 75%, mean inserted length  $340 \pm 40$  cm); there were no statistically significant differences noted after first ten procedures for the insertion time and there were no statistically significant differences regarding diagnostic yields and insertion length (Fig. 1).

The average insertion time was 92.1 (25–260) minutes per-rectally and the diagnostic yield was 81.03%; while the average insertion time was 159.6 min for the first 5 procedures (diagnostic yield was 80%, mean inserted length  $280 \pm 60$  cm), 98.4 min for 6–10 procedures (diagnostic yield was 60%, mean inserted length  $260 \pm 40$  cm), 86.6 min for 11–15 (diagnostic yield was 80%, mean inserted length  $320 \pm 80$  cm), 76.4 min for 16–20 (diagnostic yield was 100%, mean inserted length  $300 \pm 60$  cm), 82.4 min for 21–25 (diagnostic yield was 80%, mean inserted length  $280 \pm 80$  cm), 75 min for 26–30 procedures (diagnostic yield was 80%, mean inserted length  $260 \pm 80$  cm), 78.2 min for 31–35 procedures (diagnostic yield was 80%, mean inserted length  $320 \pm 40$  cm), 72.4 min for 36–40 procedures (diagnostic yield was 60%, mean inserted length  $340 \pm 60$  cm), 68.2 min for 41–45 procedures (diagnostic yield was 80%, mean inserted length  $280 \pm 80$  cm), 66.9 min for 46–50 procedures (diagnostic yield was 100%, mean inserted length  $340 \pm 40$  cm), and 42.9 min for 51–58 procedures (diagnostic yield was 87.5%, mean inserted length  $300 \pm 60$  cm); there was no statistically significant difference after first five procedures for the procedure duration and no statistically significant difference with regards to diagnostic yields and insertion length (Fig. 2).

For the different genders there was no statistically significant difference with the average insertion time being 61.2 min per-orally and 78.8 min per-rectally for males and 66.2 min per-orally and 91.8 min per-rectally for females.

Endoscopic findings were 50 angiodysplasias, 15 submucosal tumors (13 GIST and 2 lipoma), 21 small intestinal ulcers (including 3 Crohn's disease and 2 CMV enteritis), 12 diverticulum, 3 small intestinal varices, 5 Peutz-Jegher polypsis, 3 jejunal adenocarcinoma, 3 metastatic tumors, one granulation polyp, and 4 Dieulafoy lesions. The overall diagnostic yield was 82.4% (117/142). Therapeutic procedures were done in 52% (74/142) included argon plasma coagulation, hemoclipping, diluted bosmin local injection, polypectomy and endoscopic mucosal resection. There were 7 cases (14%) with angiodysplasia suffered from recurrent bleeding and received further enteroscopic hemostasis in 5 cases and operation in another 2 cases. No major complications occurred related to DBE procedures, except that 8 patients suffered from abdominal fullness after DBE.

#### 4. Discussion

Because of the free intraperitoneal location, the vigorous contractility, convolutions and the length of the small bowel, bleeding from this area is difficult to approach using conventional endoscopy.<sup>3</sup> Push enteroscopy could detect only a limited portion of the proximal small bowel. The usefulness of wireless capsule endoscopy for diagnosing obscure gastrointestinal bleeding has been clearly demonstrated, with a diagnostic yield of 30%–80%.<sup>5–12</sup> However, capsule endoscopy suffers from limitations, including the inability to provide back-and-forth detailed observation of lesion, water washing, tissue biopsy and therapeutic intervention. Furthermore, the clinical significance of certain questionable lesions detected at capsule endoscopy remains unclear.

The double-balloon enteroscopy overcame the limitation of capsule endoscopy, and in particular could carry out endoscopic treatment.<sup>16–21</sup> The diagnostic yield of double-balloon enteroscopy for suspected small bowel disease, particularly in case of obscure gastrointestinal bleeding, was 72%–80% in

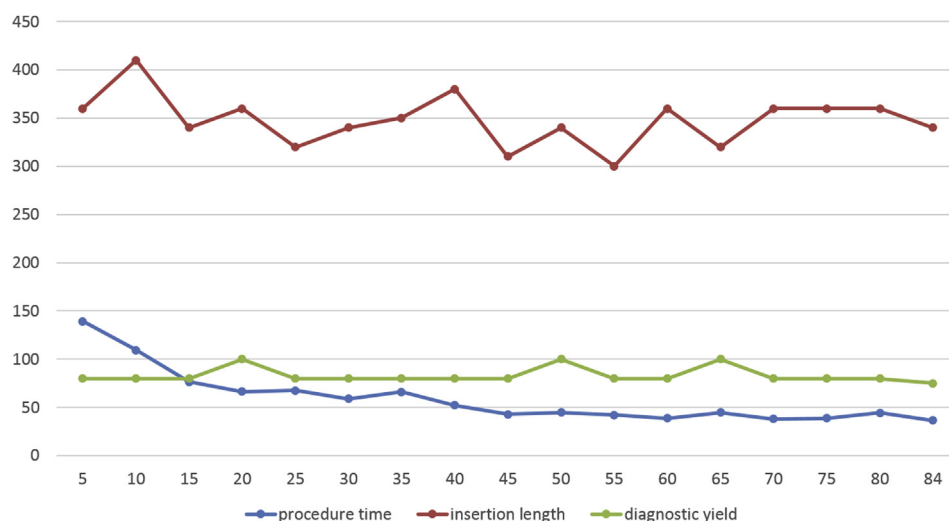


Fig. 1. The average insertion time, insertion length and diagnostic yield for DBE per-orally.

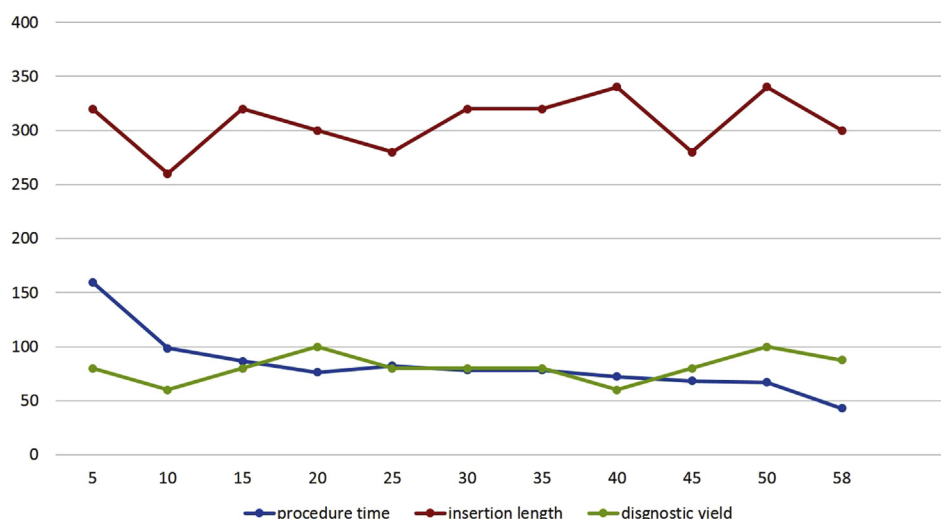


Fig. 2. The average insertion time, insertion length and diagnostic yield for DBE per-rectally.

the literature.<sup>16–21</sup> In the present series, lesions potentially responsible for gastrointestinal bleeding of obscure origin were found in 75% of the patients undergoing double-balloon enteroscopy. Angiodysplasias were the most common etiology for obscure bleeding in this study, followed by tumors and ulcers. In this study, the overall diagnostic yield was 82.3% with the major finding of angiodysplasia, similar to previous studies.

Although the DBE examination provides numerous benefits, some serious complications had been reported related to this procedure, so a learning curve associated with performing DBE is needed to become an expert. Our analysis showed a significant learning curve in acquiring the skills necessary to perform DBE. To maintain a constant and adequate diagnostic yield, the endoscopist needs to performed more than 10 cases per-orally DBE procedures and 5 cases per-rectally DBE procedures to achieve a reasonable insertion times. The average insertion time in our experience was 74.4 min per-orally and 91.5 min per-rectally. The US experiences reported a mean procedure time of 96.6 min, and the European prospective trial reported a mean procedure time of 75 min. A statistically significant trend toward shorter procedure durations was noted as endoscopists gained more experience with DBE.

The insertion time is longer for DBE per-rectally than per-orally. This may be related to the per-rectal DBE procedure needing to pass through the whole colon and get into ileocecal valve, however, some patients had a torturous and redundant colon that made the per-rectal DBE procedure more time consuming. Moreover, some patient's ileocecal valve had a difficult angle to get advances and this also required longer procedure times. Not like the colon, during the per-oral DBE procedure it is easier to push down to the small intestine. One US study reported that there was a 31% failure rate of per-rectal approach,<sup>22</sup> in the series reported by Yamamoto et al.,<sup>16</sup> the ileocecal valve was reached in all 89 cases attempted, while another studies from Germany showed

failure rates of 14% and 8%.<sup>18</sup> In our study, all the 58 cases involving DBE performed per-rectally reached to the small intestine successfully, this may be related to our operator is an experienced colonoscopist performed more than 10,000 cases of colonoscopy. There were no statistical significant differences for the procedure durations between male and female patients.

In conclusion, double-balloon enteroscopy is a safe and effective means of diagnosing and managing patients with obscure gastrointestinal bleeding. However, because of its time-consuming, DBE has a learning curve to overcome before a physician can become an expert to achieve adequate insertion times with good diagnostic and therapeutic rates.

## References

1. Zuckerman GR, Prakash C, Askin MP, Lewis BS. AGA technical review on the evaluation and management of occult and obscure gastrointestinal bleeding. *Gastroenterology* 2000;**118**:201–21.
2. Lau WY, Fan ST, Wong SH, Wong KP, Poon GP, Chu KW, et al. Pre-operative and intraoperative localization of gastrointestinal bleeding of obscure origin. *Gut* 1987;**28**:869–77.
3. Lewis BS. Small intestinal bleeding. *Gastroenterol Clin N Am* 1994;**23**: 67–91.
4. Seensalu R. The sonde examination. *Gastrointest Endosc Clin N Am* 1999; **9**:37–59.
5. Lewis BS, Swain P. Capsule endoscopy in the evaluation of patients with suspected small intestinal bleeding: results of a pilot study. *Gastrointest Endosc* 2002;**56**:349–53.
6. Pennazio M, Santucci R, Rondonotti E, Abbiati C, Beccari G, Rossini FP, et al. Outcome of patients with obscure gastrointestinal bleeding after capsule endoscopy: report of 100 consecutive cases. *Gastroenterology* 2004;**126**:643–53.
7. Rosch T. DDW report 2004 New Orleans: capsule endoscopy. *Endoscopy* 2004;**36**:763–9.
8. Keuchel M, Hagenmuller F. Small bowel endoscopy. *Endoscopy* 2005;**37**: 122–32.
9. Ell C, Remke S, May A, Helou L, Henrich R, Mayer G. The first prospective controlled trial comparing wireless capsule endoscopy with push enteroscopy in chronic gastrointestinal bleeding. *Endoscopy* 2002;**34**: 685–9.

10. Saurin JC, Delvaux M, Gaudin JL, Fassler I, Villarejo J, Vahedi K, et al. Diagnostic value of endoscopic capsule in patients with obscure digestive bleeding: blinded comparison with video push enteroscopy. *Endoscopy* 2003;**35**:576–84.
11. Adler DG, Knipschild M, Gostout C. A prospective comparison of capsule endoscopy and push enteroscopy in patients with GI bleeding of obscure origin. *Gastrointest Endosc* 2004;**59**:492–8.
12. Costamagna G, Shah SK, Riccioni ME, Foschia F, Mutignani M, Perri V, et al. A prospective trial comparing small bowel radiographs and video capsule endoscopy for suspected small bowel disease. *Gastroenterology* 2002;**123**:999–1005.
13. Yamamoto H, Sekine Y, Sato Y, Higashizawa T, Miyata T, Iino S, et al. Total enteroscopy with a nonsurgical steerable double-balloon method. *Gastrointest Endosc* 2001;**53**:216–20.
14. Su MY, Liu NJ, Hsu CM, Chiu CT, Chen PC, Lin CJ. Double balloon enteroscopy-the last blind-point of the gastrointestinal tract. *Dig Dis Sci* 2005;**62**:62–70.
15. Hsu CM, Chiu CT, Su MY, Lin WP, Chen PC, Chen CH. The outcome assessment of double-balloon enteroscopy for diagnosing and managing patients with obscure gastrointestinal bleeding. *Dig Dis Sci* 2007;**62**:162–6.
16. Yamamoto H, Kita H, Sunada K, Hayashi Y, Sato H, Yano T, et al. Clinical outcomes of double-balloon endoscopy for the diagnosis and treatment of small-intestinal diseases. *Clin Gastroenterol Hepatol* 2004;**2**:1010–6.
17. May A, Nachbar L, Ell C. Double-balloon enteroscopy(push-and-pull enteroscopy) of the small bowel: feasibility and diagnostic and therapeutic yield in patients with suspected small bowel disease. *Gastrointest Endosc* 2005;**62**:62–70.
18. Ell C, May A, Nachbar L, Cellier C, Landi B, di Caro S, et al. Push-and-pull enteroscopy in the small bowel using the double-balloon techniques: result of a prospective European Multicenter study. *Endoscopy* 2005;**37**:613–6.
19. Di Caro S, May A, Heine DG, Fini L, Landi B, Petruzzello L, et al. DBE-European study group. The European experience with double-balloon enteroscopy: indications, methodology, safety, and clinical impact. *Gastrointest Endosc* 2005;**62**:545–50.
20. Kaffes AJ, Koo JH, Meredith C. Double-balloon enteroscopy in the diagnosis and the management of small-bowel diseases: an initial experience in 40 patients. *Gastrointest Endosc* 2006;**63**:81–6.
21. Heine GD, Hadithi M, Groenen MJ, Kuipers EJ, Jacobs MA, Mulder CJ. Double-balloon enteroscopy: indications, diagnostic yield, and complications in a series of 275 patients with suspected small-bowel disease. *Endoscopy* 2006;**38**:42–8.
22. Mehdizadeh S, Ross A, Gerson L, Leighton J, Chen A, Schembre D, et al. What is the learning curve associated with double-balloon enteroscopy? Technical details and early experience in 6 U.S. tertiary care centers. *Gastrointest Endosc* 2006;**64**:740–50.